



Keywords

Immediate Implant Placement,
Socket-Shield

Received: August 31, 2014

Revised: December 16, 2014

Accepted: December 17, 2014

Conventional immediate implant placement and immediate placement with socket-shield technique – Which is better

Abadzhiev M.¹, Nenkov P.², Velcheva P.³

¹Medical University – Varna, Bulgaria. Faculty of dental medicine, Department of Prosthodontics and Orthodontics

²Medical University – Varna, Bulgaria. Faculty of dental medicine, Department of Periodontology and Implant dentistry

³Medical University – Varna, Bulgaria. Faculty of dental medicine, Department of Conservative treatment and Oral pathology

Email address

abaimplant@abv.bg (Abadzhiev M.), pl.nenkov@gmail.com (Nenkov P.),

polina_velcheva87@abv.bg (Velcheva P.)

Citation

Abadzhiev M., Nenkov P., Velcheva P.. Conventional Immediate Implant Placement and Immediate Placement with Socket-Shield Technique – Which is Better. *International Journal of Clinical Medicine Research*. Vol. 1, No. 5, 2014, pp. 176-180.

Abstract

Implantology in visible frontal region demands extreme precision due to the high aesthetic requirements of patients. Years of age immediate implant placement was considered main approach for preserving bone volume after tooth extraction due to its close relation to the tissues to the periodontal ligaments. Therefore a risk of losing vestibular bone height and respectively soft tissue which is unacceptable from aesthetic point of view. One of the methods used in order to avoid bone loss is the so called “socket-shield” technique published by Dr. Marc Hürzler and Dr. Otto Zuhr. Comparison of the results gained after immediate implant placement by conventional and socket-shield techniques for a period of two years, 26 titanium screwed implants placed in post-extraction socket with conventional immediate implantation and socket-shield technique, xenogenic bone-graft material, PRGF, individualized factory titanium abutments, zirconium individual abutments with titanium interface, press-ceramic E-max, metal-ceramic. Sector x-rays and intraoral photos for determining bone and soft tissue loss after immediate implant placement. It was discovered minimal from functional point of view but unacceptable form aesthetic point of view vertical bone loss of the vestibular lamella at conventional implant placement. To compare in socket-shield technique there were neither functional nor aesthetic changes in soft and hard tissues. Socket-shield technique is already a routine practice in the arsenal of high-aesthetic immediate implantology and should be used when it is indicated.

1. Introduction

There is a dramatic remodeling of hard and soft tissues after tooth extraction. Data reported in clinical studies indicate that an overall reduction in the horizontal dimensions occurred following tooth extraction and that the resorption of the buccal part of the ridge was more pronounced than the lingual part (Pierokovsky and Massler 1967, Schropp et. al. 2003). Similar observations were also made on histological evaluation in an animal experiment by Lindhe¹ and Araújo (2005). In this way morphology of the healed alveolar ridge following tooth extraction is almost always presenting with discrepancy in bone height between the two bone plate of the alveolar ridge – lingual and buccal. It is known that physiology processes taking place immediately after tooth extraction up to the end

of the 1st week include increasing the number of osteoclasts on the outside as well as on the inside of the buccal and lingual bone walls. The presence of osteoclasts on the inner surface of the socket walls indicates that the bundle bone, which is closely related with the periodontal tissue is being resorbed. Anatomically buccal bone plat of the teeth is thinner than lingual or palatal. There for as bundle bone is tooth-dependent tissue it will gradually disappear after extraction, Thus, since there is more bundle bone in the crest of the buccal than the lingual wall, hard tissue loss will become most pronounced in the buccal wall (Lindhe, Clinical periodontology and implant dentistry, 2008)².

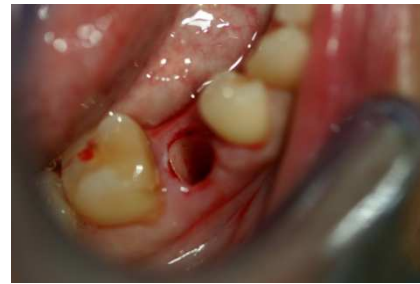These scientific evidences and the empirical experience of immediate implant placement in fresh extraction sockets have led the thought that probably by preserving the periodontal tissues on the buccal part of the socket we could prevent bone resorption in this critical area. Several authors pointed out that after immediate implant placement and loading occurrence of recession is often observed. The percentage of appearance is different in the different studies mainly because of the difficulty in predicting the behavior of soft tissue after immediate implantation.

A number of authors wonder whether guided bone regeneration with combination of immediate implant placement could compensate the physiologic bundle bone resorption. By using prospective multicenter study Becker and colleagues³ consider this problem. It appeared that membrane exposure is observed in 20 out of 49 extraction sockets treated with guided bone regeneration and immediate implant placement. In 2010 Hürzler and colleagues introduce a new approach for immediate implantation in extraction sockets of teeth with healthy periodontal tissues. By retention of the buccal root fragment of the extracted tooth far more promising results are achieved on the buccal crest bone⁴.

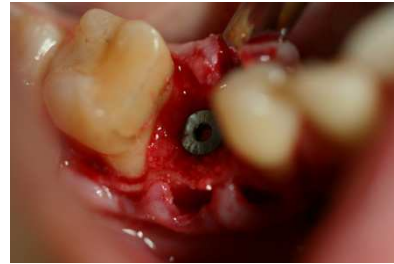
2. Materials and Methods

Study design: Twenty-six implants in twenty-five patients between 20 and 64 years of age with a need of tooth replacement in frontal aesthetic region, visible during smile. Sixteen implants placed by conventional immediate implantation and guided bone regeneration. Ten implants placed using Socket-shield technique. All cases are performed by using titanium screwed implants placed in post-extraction socket with conventional immediate implantation and socket-shield technique, kseno-bone-graft material, platelet rich in growth factors extracted from the patients' blood, Er-YAG laser granulation tissue ablation in order to assure complete health of the remaining periodontal tissue and clean socket, individualized factory titanium abutments, zirconium individual abutments with titanium interface and finished with press-ceramic E-max or metal-ceramic crowns. All cases are followed up within 2 years. All implants are evaluated by:

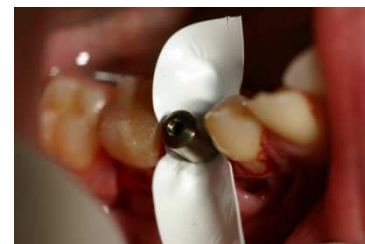1. X-ray follow up on each 6 months
2. Soft tissue volume
3. Aesthetic evaluation according to the doctor and according to the patient



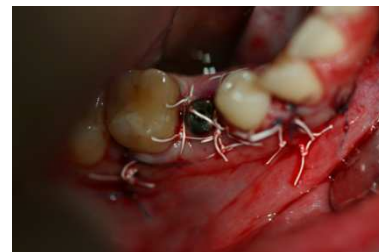(a)



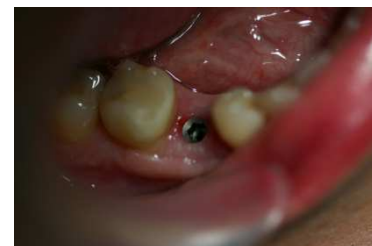(b)



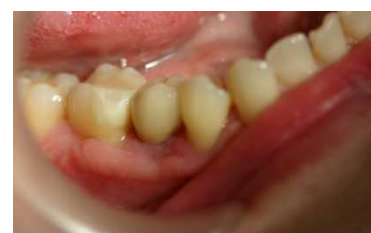(c)



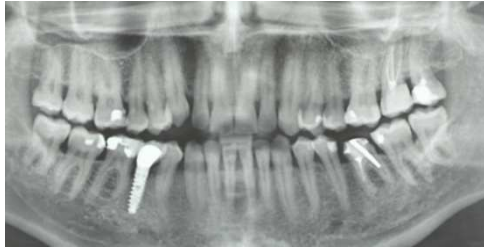(d)



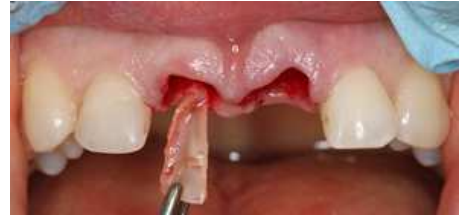(e)



(f)

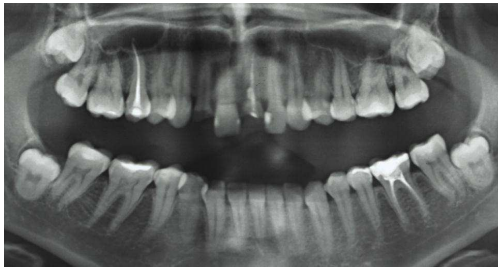

(g)

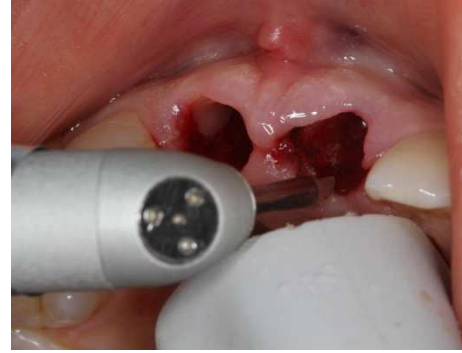

(f)

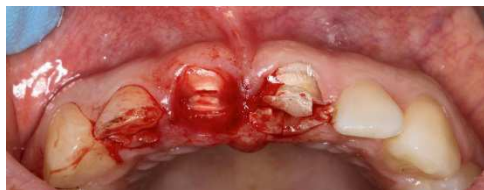Fig 1. Conventional immediate implantation (a) extraction of 45; (b) immediate implant placement; (c); bone graft and membrane placement (d) sutures ; (e)situation before impression, note the inevitable scar due to the membrane; (f)permanent crown; (g) x-ray.



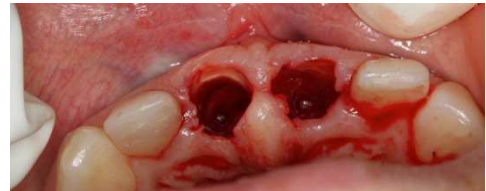(a)



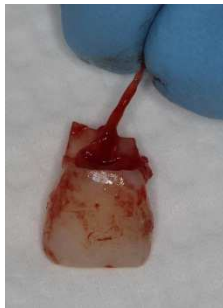(g)



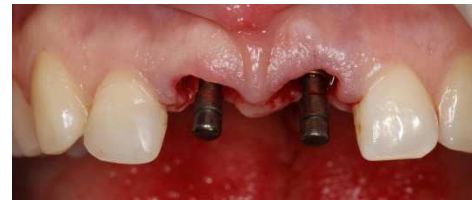(b)



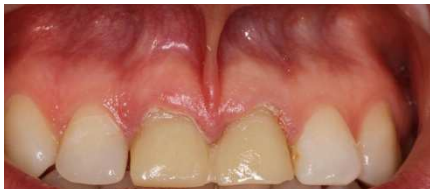(h)



(c)



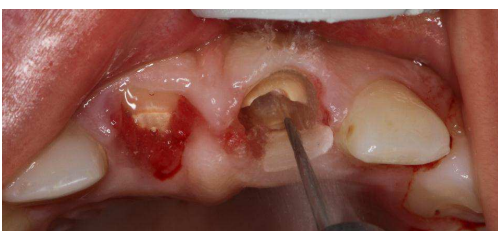(i)



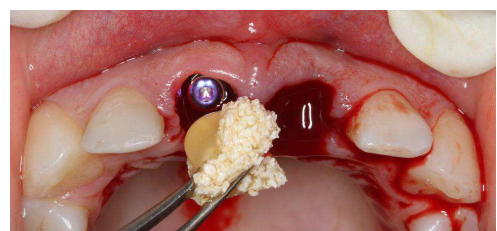
(d)



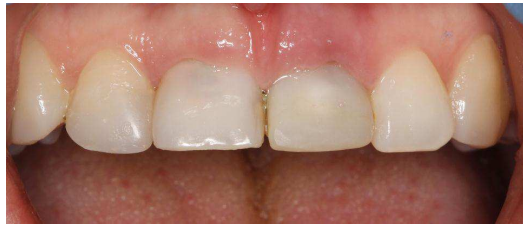(j)



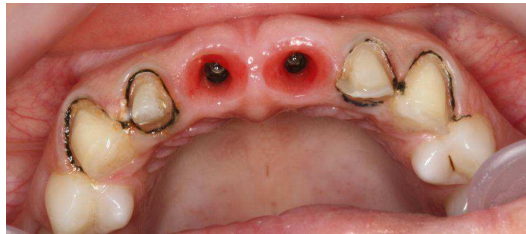
(e)



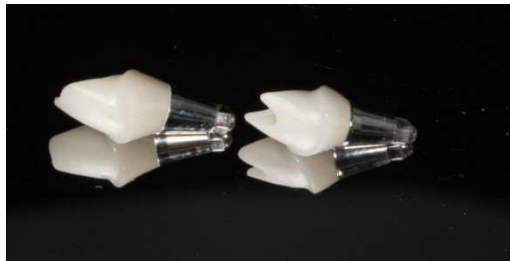(k)



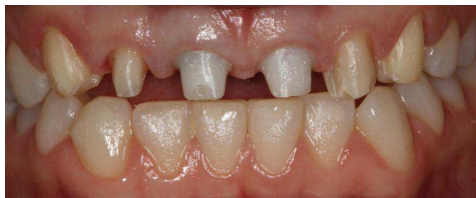(l)



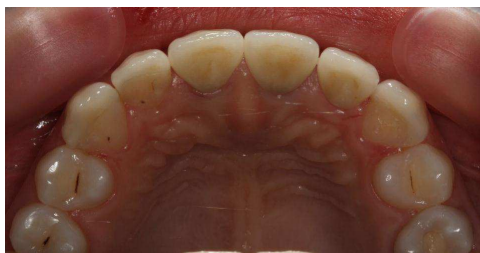(m)



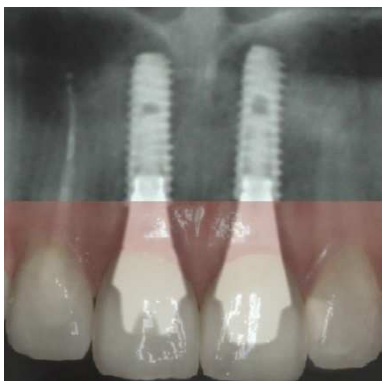(n)



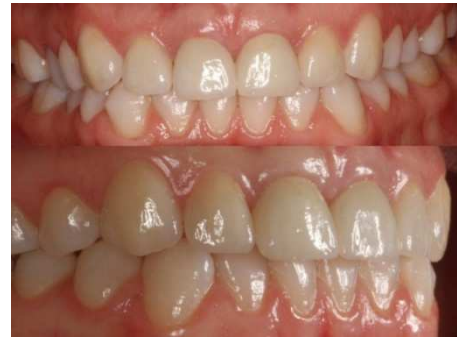(o)



(p)



(q)



(r)

Fig. 2. Socket-shield immediate implantation technique (a) initial x-ray; (b), (c) initial intraoral situation; (d) temporary construction during endo-treatment on I2 and perio treatment with ER-YAG laser before socket-shield technique; (e), (f), (g), (h), (i) socket-shield procedure; (j) PRGF activation of the implant surface; (k) bone graft mixed with prgf for compacting the remaining space around implant; (l) provisional immediate crowns; (m) healthy soft tissues; (n) individual zirconium abutments; (o) healthy soft tissues; (p), (q), (r) final result

3. Results

The result from the radiological examination immediately after implantation and on every 6 months during the next 2 years shows considerable bone loss in conventional implantation. Up to 12% in the first two years, which is equal up to 5mm. Contrary in socket-shield technique during 2 years follow up bone loss is 2% which is equal to 0.8mm.

Soft tissue volume is assessed by the quantity of attached gingiva. Almost same results are observed in this criteria as in the bone loss. 18% compared with 2% in favor of the socket-shield technique. High bone resorption leads to lack of soft tissue support and is a precondition for mucogingival surgery for increasing the volume of attached soft tissue.

The result from the clinical assessment of aesthetics showed the predominant natural appearance of socket-shield treated teeth.

After all we are mimic the nature and clinical result analysis show much more natural look of the implants placed by using socket-shield technique.

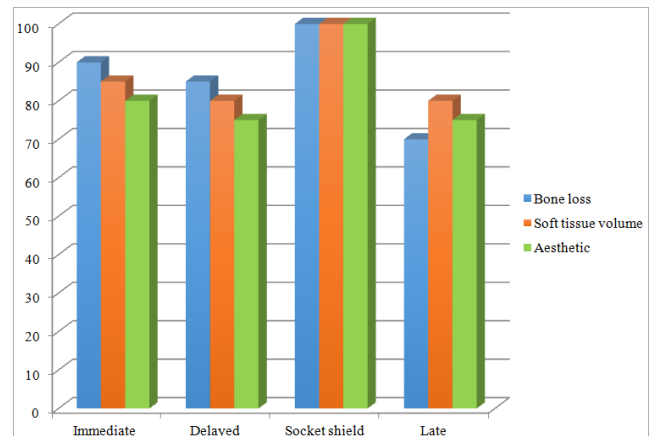


Fig. 3. Evaluation in percentage of bone loss, soft tissue volume and aesthetic in cases of conventional immediate implant placement, socket-shield technique and even compared with delayed and late implantation⁵.

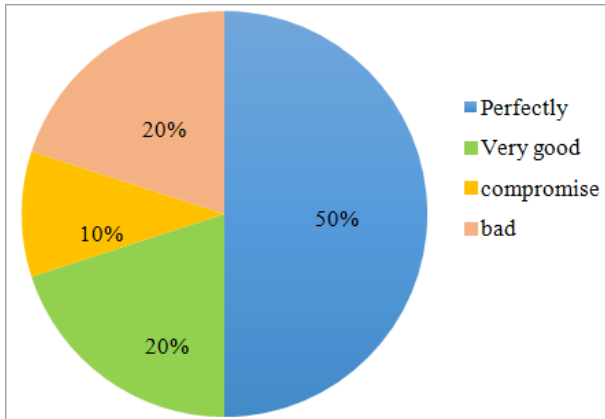


Fig. 4. Aesthetic evaluation according to the doctor and according to the immediate implant placement patients based on questionnaire survey

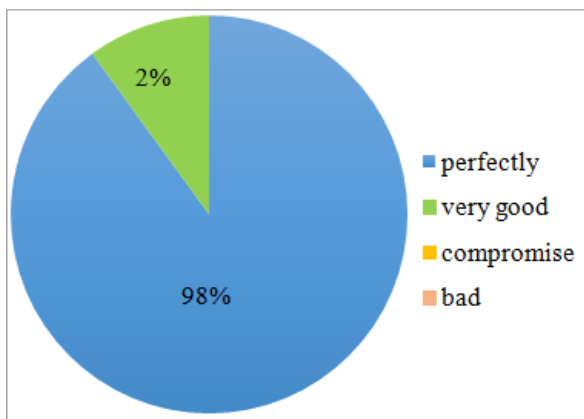


Fig. 5. Aesthetic evaluation according to the doctor and according to the socket-shield implant placement patients based on questionnaire survey

4. Discussion

In the present report bone loss, soft tissue volume and aesthetic evaluation were used in order to prove that socket-shield technique is much more promising strategy for immediate implant placement due to the fact that preserving vestibular root fragment leads to preserving bundle bone and in this way preserving buccal bone volume.

5. Conclusion

Long-term clinical studies and observations are needed in order to prove positively the extreme importance of

preserving buccal root fragment in order to assure high aesthetic results as well as extremely high long-lasting implantology outcomes. The biology of tissues is the key for constant, stable results especially in a recently unpredictable field as immediate implant placement in an extraction socket. The more we imitate and preserve natural vital tissues the more good-looking aesthetic results we achieve.

In vivo studies as well as our improved version of socket shield technique by using our biological concept prove that excellent results are achievable. By combining separate biological actions like platelet rich in growth factors extracted from the patients' blood, Er-YAG laser granulation tissue ablation in order to assure complete health of the remaining periodontal tissue and clean socket, individualized factory titanium abutments, zirconium individual abutments with titanium interface and finished with press-ceramic E-max or metal-ceramic crowns, each one of them one by one approved as appropriate approaches confirms that one plus one in medicine could be three:

1. Lack of bone loss
2. Sufficient soft tissue volume
3. Excellent aesthetic results

In other words science and technologies guides us to desired results by using the most valuable prove in medicine – in vitro cases.

References

- [1] Araújo, MG and Lindhe, J (2005). Dimensional ridge alterations following tooth extraction. An experimental study in dogs. *Journal of clinical periodontology* 32: 212-218.
- [2] Lindhe, J (2008) *Clinical periodontology and implant dentistry*
- [3] Becker W. et al. The use of ePTFE barrier membranes for bone promotion around titanium implants placed into extraction sockets: A prospective multicenter study, *Oral Maxillofac Implants* 1994; 9:31-40
- [4] Hürzler MB, Zuht O, Schüpback P, The Socket-shield technique. A proof-of-principle report. *J Clinical Periodontology* 2010; 37:855-862
- [5] Abadzhiev M. Socket shield technique as an alternative of conventional immediate implantation, IMAB 2014.